

## CASE REPORT

# Quackery: Consequence and Advance

<sup>1</sup>Swati Sharma, <sup>2</sup>Anupriya Jha, <sup>3</sup>Virendra K Prajapati, <sup>4</sup>Sumaiya Nezam, <sup>5</sup>Sunita Singh

## ABSTRACT

The practice of quackery in dentistry is a threat as it challenges the trust of the patients and places the patients at unnecessary risks through their illegal practices. Most commonly, dental quacks are the self-styled experts, whose basic tools are very incompetent and also pretentious. This is a case report of a 12-year-old girl with anterior teeth fracture who fell prey to two such fraudulent dental practitioners over a period of 2 years.

**Keywords:** Apicoectomy, Mineral trioxide aggregate, Quackery.

**How to cite this article:** Sharma S, Jha A, Prajapati VK, Nezam S, Singh S. Quackery: Consequence and Advance. *Int J Adv Integ Med Sci* 2018;3(1):44-47.

**Source of support:** Nil

**Conflict of interest:** None

## INTRODUCTION

The practice of fraud or deception in dentistry is a challenge to the profession as it shackles the trust of the public and projects the patients at unwanted risks through their illegal practices. Most commonly, quacks are the self-styled experts, whose basic tools are very incompetent and also pretentious.<sup>1</sup> Currently, India has one dentist per 10,000 population in urbanized areas and one in about 2.5 lakh in rural areas. The exuberant cost of dental treatment, high rate of illiteracy, lack of awareness, poor accessibility to dental facilities, and numerous dental appointments are the causes for which most patients rely on these quacks. Also, quacks guarantee their patients painless and immediate treatment. The people residing in rural areas resort blindly and faithfully to such treatments rendered by unqualified medical healers. Most of the quacks learn some dental work while working

as assistants in private dental clinics. They are able to acquire a meager knowledge by just observing the dental operating procedures with no scientific knowledge and then start their own practice in rural areas at a low cost, without using any technology and modalities. They are least concerned about the sterilization of their instruments and devise their own instruments according to their convenience, which has no scientific basis.<sup>2</sup> This is a case report of a patient who fell prey to the hands of two such quacks.

## CASE REPORT

A 12-year-old girl reported with pain and swelling in the upper front region which she had been experiencing from the past 2 months. Crown fracture was present in 12, 11, and 21 (Fig. 1). Past dental history revealed that the child had endured trauma in the upper anterior region 1.5 years back due to a fall while she was playing and had been treated at two different private dental practices. The first practitioner had performed root canal therapy followed by apicoectomy in the involved teeth without placement of any obturating material. The patient reported that practitioner kept recalling her for about an entire year, but failed to provide any kind of relief to the patient. The patient then consulted another private practitioner who obturated the canals with gutta-percha.

Orthopantomogram revealed that the involved teeth had been reduced to half of the original root size of each tooth to approximately half its original length of ~10 mm (Fig. 2).

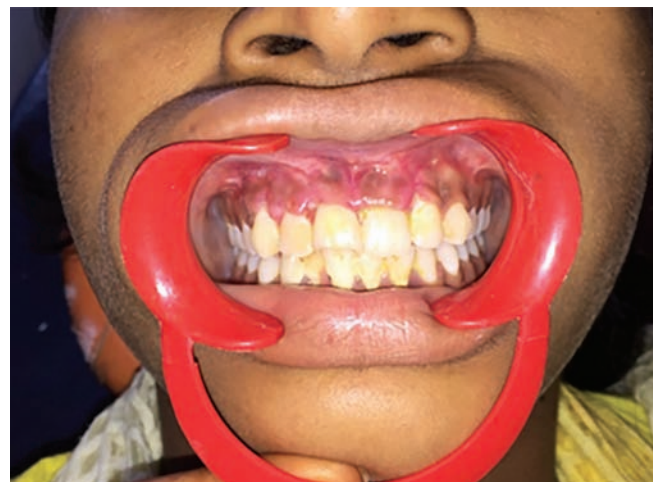

Fig. 1: Preoperative photograph of the child

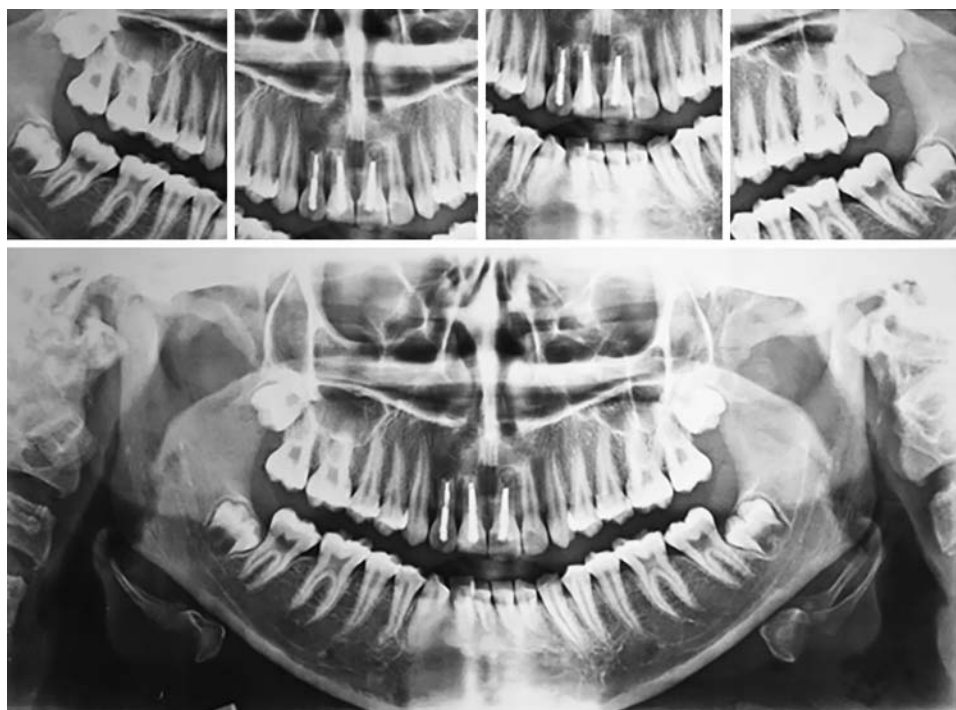
<sup>1</sup>Lecturer, <sup>2,4,5</sup>Postgraduate Trainee, <sup>3</sup>Professor and Head

<sup>1</sup>Department of Pedodontics and Preventive Dentistry, Dental Institute, Rajendra Institute of Medical Sciences, Ranchi Jharkhand, India

<sup>2,4,5</sup>Department of Pedodontics and Preventive Dentistry Buddha Institute of Dental Sciences & Hospital, Patna, Bihar India

<sup>3</sup>Department of Oral & Maxillofacial Surgery, Dental Institute Rajendra Institute of Medical Sciences, Ranchi, Jharkhand, India

**Corresponding Author:** Anupriya Jha, Postgraduate Trainee Department of Pedodontics and Preventive Dentistry, Buddha Institute of Dental Sciences & Hospital, Patna, Bihar, India Phone: +918084079718, e-mail: anupriyajhamw@gmail.com



**Fig. 2:** Orthopantomogram showing the involved teeth reduced to half

### Treatment Plan

Immediately after thorough clinical and radiological evaluation of the patient, the gutta-percha was removed from each canal followed by copious irrigation of the canals. Metapex was placed inside the canals followed by glass ionomer cement. The patient was prescribed antibiotics and nonsteroidal anti-inflammatory drugs for 5 days. After 21 days, the patient was recalled and reported to be asymptomatic.

Root-end filling of mineral trioxide aggregate (MTA) was planned to seal the severed roots of the involved teeth. Patient and her parents were explained about the procedure, and a written consent was obtained. A complete hemogram of the patient was done, which revealed

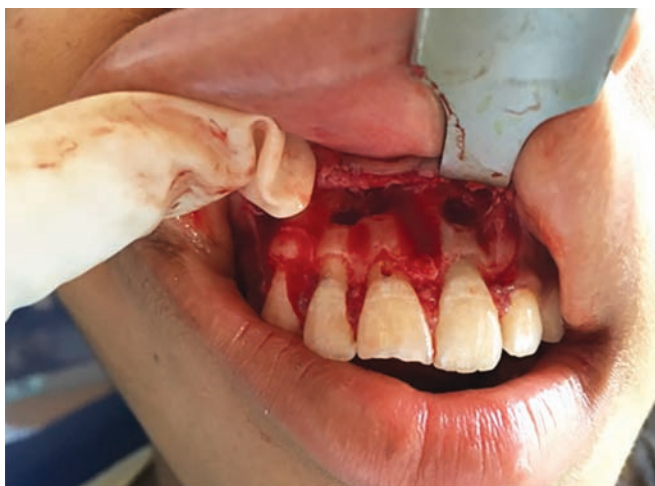no abnormalities. Preanesthetic evaluation of the patient was done.

Under local anesthesia, a full-thickness flap was raised and the roots of the involved teeth were exposed. Iatrogenic perforations of the labial cortical plate were evident along with large holes at the apical portion of the involved teeth (Fig. 3).

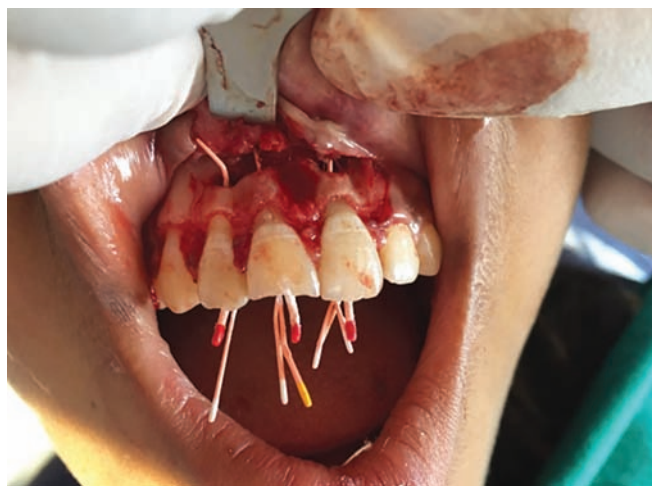Surgical curettage of the periapical pathological tissue was done.

After obturating the canals with gutta-percha (Fig. 4), MTA (Fig. 5) was placed to seal the above-mentioned perforations.

The flap was sutured to its original position, and the patient was given postoperative instructions.



**Fig. 3:** Iatrogenic perforations of the labial cortical plate with large holes at the apical portion



**Fig. 4:** After obturating the canals with gutta-percha

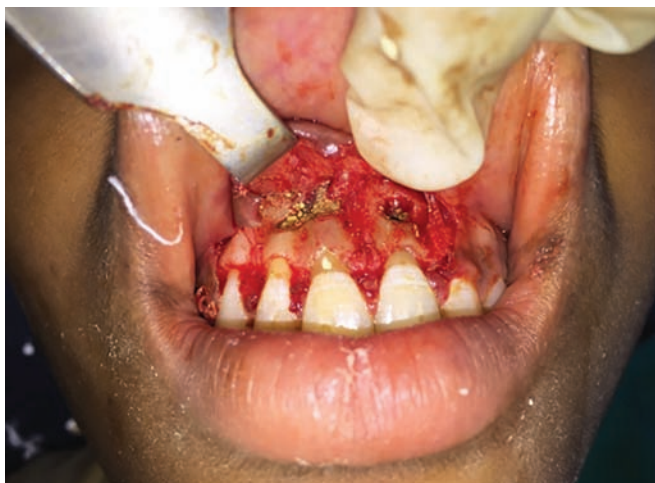

Fig. 5: MTA placed to seal the perforations

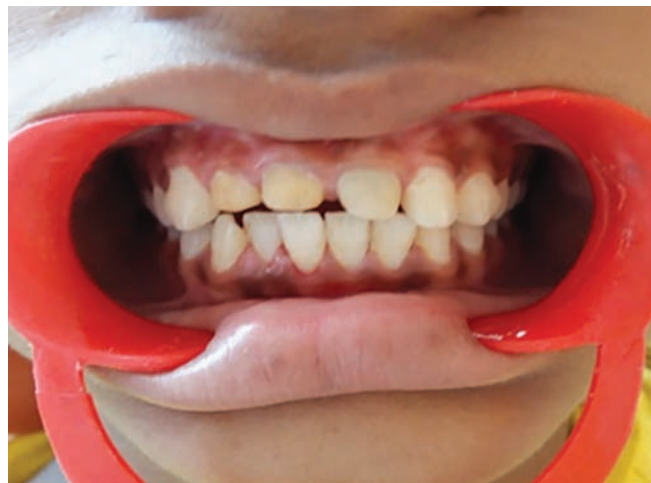

Fig. 6: Tooth preparation and shade selection

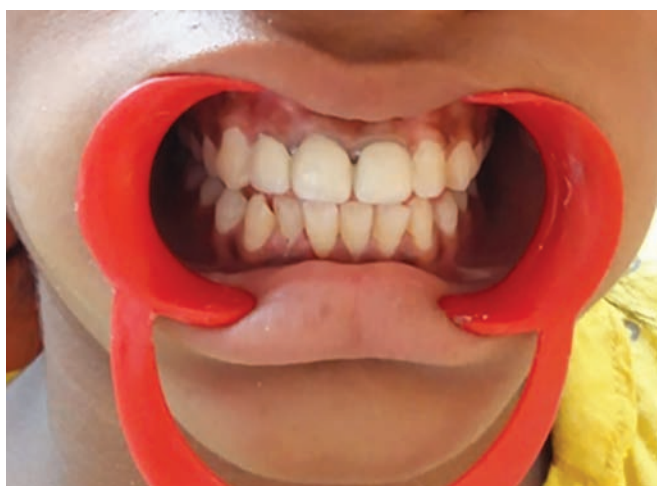

Fig. 7: Full veneer crowns given

The patient was recalled after a week, the sutures were removed, and no swelling, redness, or pain was seen.

The patient was recalled after 15 days for fabrication of full veneer crowns. Tooth preparation and shade selection were done on the first appointment (Fig. 6). Full veneer crowns were given in the second appointment (Fig. 7).

## DISCUSSION

Periapical surgery is considered a standard minor oral surgical procedure. It is often regarded as a last resort to surgically maintain a tooth with a periapical lesion that cannot be managed with conventional endodontic (re-) treatment. The main aim of apical surgery is to prevent any microbial leakage from the root canal system into the periradicular tissues by placing a root-end filling following root-end resection.<sup>3</sup>

Indications for apical surgery have been recently updated by the European Society of Endodontology, 2006, and include the following<sup>4</sup>:

- Radiological findings of apical periodontitis and/or symptoms associated with an obstructed canal (the

obstruction proved not to be removable, displacement did not seem feasible, or the risk of damage was too great);

- Extruded material with clinical or radiological findings of apical periodontitis and/or symptoms continuing over a prolonged period;
- Persisting or emerging disease following root canal treatment when root canal retreatment is inappropriate; and
- Perforation of the root or the floor of the pulp chamber and where it is impossible to treat from within the pulp cavity.

The objective of apicoectomy is to remove a persistent periapical lesion, prevent its recurrence, and promote tissue repair.<sup>5</sup> But in this case, neither was achieved due to lack of knowledge, skill, and improper planning.

Mineral trioxide aggregate (Angelus) was used as a root-end filling material and for perforation repair in this case. The MTA was chosen as the material of preference in the present case due to its sealing ability, biocompatibility, bactericidal effect, radiopacity and its successful use as root-end filling material, in surgical repair, pulp capping, apexification, radicular resorption, and perforations.<sup>6</sup> Mineral trioxide aggregate appears to have become the gold standard for a root-end filling material. All studies published to date have reported higher success rates for MTA than for the competitor material.<sup>7,8</sup>

The practitioners who treated the child earlier failed to understand the importance of the crown–root ratio. Short dental roots resulting in unfavorable crown-to-root ratios can affect the prognosis of teeth<sup>9</sup> and increase the periapical stress.<sup>10</sup> This displayed the practitioner's lack of knowledge and compromised skill.

Both the practitioners also failed to understand that root-end preparation and filling may be necessary to promote the hermetic sealing of the root canal system.

## CONCLUSION

Dentistry faces serious problems regarding accessibility of its services to all in India. The major missing link is the absence of a primary health care approach. Due to significant geographic imbalance in the distribution of dental colleges, a great variation in the dentist-to-population ratio in the rural and the urban areas is seen. Reports suggest that there are about more than one million unqualified dental health care providers, or “quacks,” in India. They have long been blamed for misdiagnosing and mistreating dental diseases.

## REFERENCES

1. Chauhan H, Potlia I, Purohit N, Mallick S. Is quackery still a parallel world of dentistry—a case report. *Int J Oral Health Med Res* 2016 Sept-Oct;3(3):59-63.
2. Hans MK. Quackery: a major loophole in dental practice in India. *J Clin Diagn Res* 2014; Feb;8(2):283.
3. Von Arx T. Apical surgery: a review of current techniques and outcome. *Saudi Dent J* 2011 Jan;23(1):9-15.
4. European Society of Endodontology. Quality guidelines for endodontic treatment: consensus report of the European Society of Endodontology. *Int Endod J* 2006 Dec;39(12):921-930.
5. Post LK, Lima FG, Xavier CB, Demarco FF, Gerhardt-Oliveira M. Sealing ability of MTA and amalgam in different root-end preparations and resection bevel angles: an *in vitro* evaluation using marginal dye leakage. *Braz Arch Biol Technol* 2010;21(5):416-419.
6. Hariharavel VP, Ashok Kumar A, Annamalai S, Aravindhan R, Ramar K. Repair of perforation with mineral trioxide aggregate (MTA). *IOSR J Dent Med Sci* 2014 Jan;13(1):61-64.
7. Chong BS, Pitt Ford TR, Hudson MB. A prospective clinical study of mineral trioxide aggregate and IRM when used as root-end filling materials in endodontic surgery. *Int Endod J* 2003 Aug;36:520-526.
8. Lindeboom JA, Frnken JW, Valkenburg P, van den Akker HP. The role of preoperative prophylactic antibiotic administration in periapical endodontic surgery: a randomized, prospective double-blind placebo-controlled study. *Int Endod J* 2005 Dec;38:877-881.
9. Hölttä P, Nyström M, Evälahti M, Alaluusua S. Root-crown ratios of permanent teeth in a healthy Finnish population assessed from panoramic radiographs. *Eur J Orthod* 2004 Oct;26(5):491-497.
10. Liu L, Li H, Zhao T, Gao Y, Guo J, Wang X, Li X. Crown-to-root ratios in terms of length, surface area and volume: a pilot study of premolars. *Int J Morphol* 2016;34(2):465-470.